Arthroscopically Assisted Acromioclavicular and Coracoclavicular Ligament Reconstruction for Chronic Acromioclavicular Joint Instability

Frank Martetschläger, M.D., Mark Tauber, M.D., Peter Habermeyer, M.D., and Nael Hawi, M.D.

Abstract: Acromioclavicular (AC) joint injuries are common injuries, especially in the young and active, male population. AC joint injuries account for 12% of all injuries of the shoulder girdle in the overall population. Although conservative treatment is recommended for Rockwood type I and type II injuries, there is controversial debate about optimal treatment for type III injuries. High-grade injuries are typically treated operatively to avoid painful sequelae. A vast number of different surgical methods have been described over the past few decades. Recent advances in arthroscopic surgery have enabled the shoulder surgeon to treat acute and chronic AC lesions arthroscopically assisted. Clinical studies have already shown good and reliable results. Although surgeons agree that a biological augmentation is required to minimize the risk of recurrent instability in chronic cases, a gold standard still needs to be defined. We present an arthroscopically assisted biological augmentation technique to reconstruct the AC and coracoclavicular ligaments, protected by a button-suture tape construct for chronic AC joint instability. The presented arthroscopic biological augmentation technique uses less and/or smaller drill holes in the clavicle and coracoid than previously described, thus reducing weakening of the bony structures. At the same time it enhances both horizontal and vertical stability.

Acromioclavicular (AC) joint injuries are common injuries, especially in the young and active male population. AC joint injuries account for 12% of all injuries of the shoulder girdle in the overall population.[1,2]

Especially soccer, hockey, football, rugby, biking, and skiing are the most common sports, with highest prevalence in 20- to 30-year-old patients.[2]

There is a wide consensus about Rockwood type I and II AC joint injuries to be treated nonoperatively.[3,4] The treatment option of Rockwood type III AC joint injury is still discussed controversially in the literature, because clinical studies could not show significant advantage for treatment.[5]

Different surgical methods are described for surgical treatment and could be separated into the following categories: (1) anatomic (reproduction conoid and trapezoid ligaments), (2) nonanatomic (reproduction of a single coracoclavicular [CC] ligament without the use of internal fixation hardware), and (3) nonanatomic open reduction internal fixation using hardware.[6]

Weinstein et al.[7] and Rolf et al.[8] suggest that early surgical treatment of injuries of type III may result in superior clinical outcome than patients undergoing surgical treatment later than 3 months after injury.

Failed conservative treatment for acute AC joint instability or failed surgical stabilization can lead to chronic instability. Although a rare condition, chronic instability of the AC joint can lead to tremendous impairment of shoulder function including muscle fatigue, scapular dyskinesia, subjective sensation of heaviness of the injured upper limb, and painful horizontal adduction.[9]

Today, surgeons widely agree that a biological augmentation is required in chronic cases to enhance the healing potential of the torn structures.[8,10,11]

Laboratory studies showed that anatomic reconstruction with double graft tendons showed native-like

From the Department of Shoulder and Elbow Surgery, ATOS Clinic Munich (F.M., M.T., P.H., N.H.); Department of Orthopaedic Sports Medicine, Klinikum rechts der Isar, Technical University Munich (F.M.), Munich, Germany; Department of Traumatology and Sports Injuries, Paracelsus Medical University (M.T.), Salzburg, Austria; and Trauma Department, Hannover Medical School (N.H.), Hannover, Germany.

The authors report the following potential conflict of interest or source of funding: F.M., M.T., and P.H. are consultants for Arthrex.

Received April 13, 2016; accepted July 20, 2016.

Address correspondence to Nael Hawi, M.D., ATOS Clinic, Department of Shoulder and Elbow Surgery, Effnerstraße 38, 81925 München, Germany. E-mail: hawi.nael@mh-hannover.de

2212-6287/16308

http://dx.doi.org/10.1016/j.eats.2016.07.014

Table 1. Advantages and Disadvantages

Advantages	Disadvantages
Small drill holes	Need for graft (auto- or allograft)
Only one drill hole in the distal clavicle and coracoid	Only for experienced shoulder surgeons
Biological augmentation for acromioclavicular and coracoclavicular ligaments	Learning curve and time for surgery
Little soft-tissue damage through an arthroscopically assisted technique	

biomechanical properties[12] and clinical data showed promising results.[9,13] With the progress of arthroscopic techniques, arthroscopically assisted techniques for graft reconstruction of the AC joint have been described.[10,14] For chronic cases usually open or arthroscopically assisted procedures for graft augmentation have been proposed.[12,14,15]

For anatomic reconstruction of the CC ligaments, bone tunnels are commonly used, which increase the risk of postoperative fracture and decrease the strength of the clavicle and the coracoid process.[16-19]

Recent biomechanical studies support smaller diameters of the drill holes and using less drill holes to reduce weakening of the bone.[17,18]

We present an arthroscopically assisted technique for biological augmentation of the AC and CC ligaments using 2 small bone tunnels within the acromion and only 1 small CC bone tunnel (Table 1).

Surgical Technique

The surgical technique is shown in Video 1. The patient is placed in the beach chair position. The indexed shoulder and knee are prepared and draped freely.

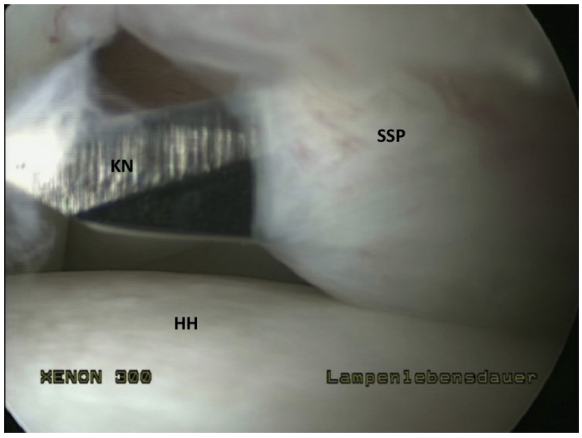

Fig 2. Beach chair position, right shoulder, arthroscopic view from the posterior portal. A high trans-supraspinatus portal is established directly behind the long head of the biceps. The arthroscope is then switched into this portal for better visualization of the subcoracoid space. Care must be taken not to damage the rotator cable. (HH, humeral head; KN, knife; SSP, supraspinatus tendon.)

Step 1: Graft Harvest

The gracilis tendon is harvested in a standard fashion. Both ends of the graft are prepared with No. 2 Ethibond suture creating torpedo-shaped graft ends.

Step 2: Diagnostic Arthroscopy

The standard posterior portal is established and diagnostic arthroscopy is performed. Concomitant intra-articular pathologies are treated first if necessary.

Step 3: Portal Placement

First an anteroinferolateral working portal is established within the rotator interval. Care must be taken to preserve the superior and middle glenohumeral

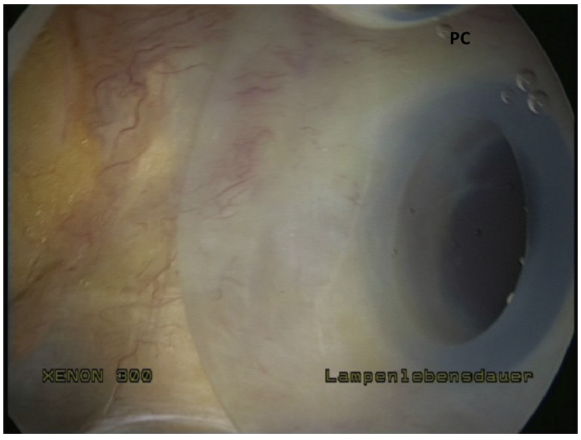

Fig 1. Beach chair position, right shoulder, arthroscopic view from the posterior portal. An anteroinferolateral working portal is established within the rotator interval, and a flexible passport cannula (PC) (Arthrex, 4 cm) is inserted to facilitate suture and graft management.

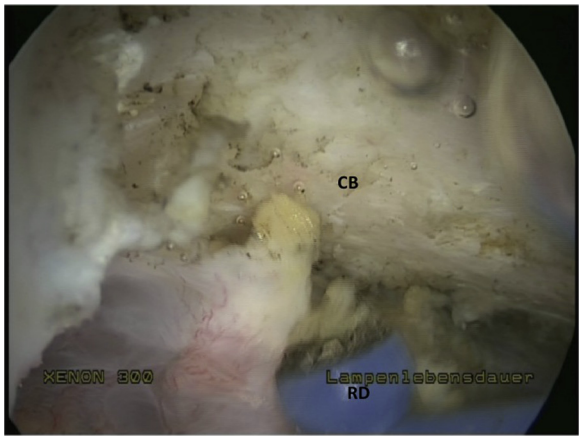

Fig 3. Beach chair position, right shoulder, arthroscopic view from the trans-supraspinatus portal. Under direct visualization the undersurface of the coracoid is skeletonized (undersurface of coracoid base [CB]) using a radiofrequency device (RD) (OPES, Arthex) through the anteroinferolateral portal.

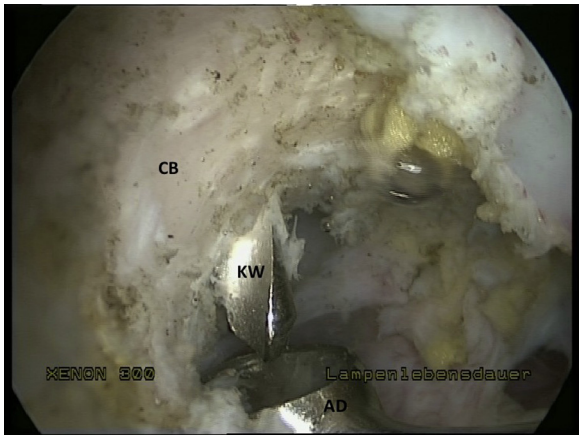

Fig 4. Beach chair position, right shoulder, arthroscopic view from the trans-supraspinatus portal. A drill guide is used to place a K-wire (KW) through the distal clavicle at the level between the conoid and trapezoid ligament insertion and through the central portion of the coracoid base (CB) using an aiming device (AD).

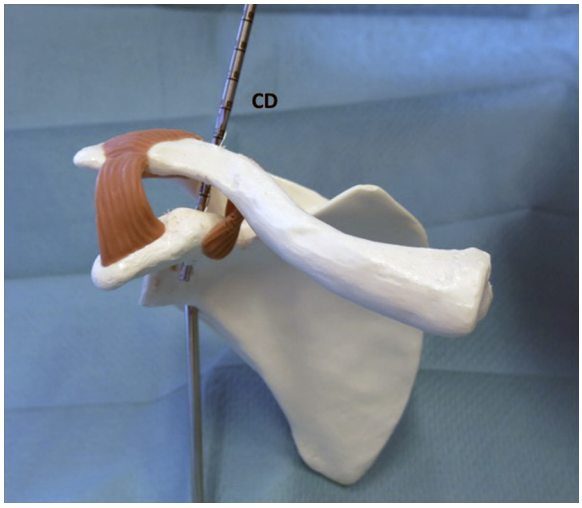

Fig 5. Shoulder model, right shoulder, after the confirmation of correct positioning through fluoroscopy. The K-wire is overdrilled using a cannulated 4-mm drill (CD) and the K-wire is removed.

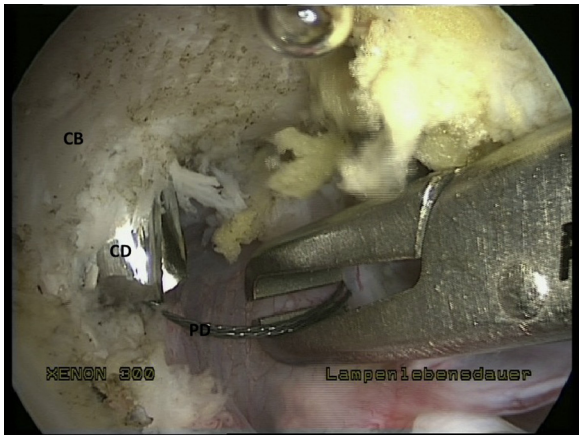

Fig 6. Beach chair position, right shoulder, arthroscopic view from the trans-supraspinatus portal. A suture passing device (PD) is inserted through the cannulated drill (CD) and removed through the anteroinferolateral portal using a conventional grasper. (CB, coracoid base.)

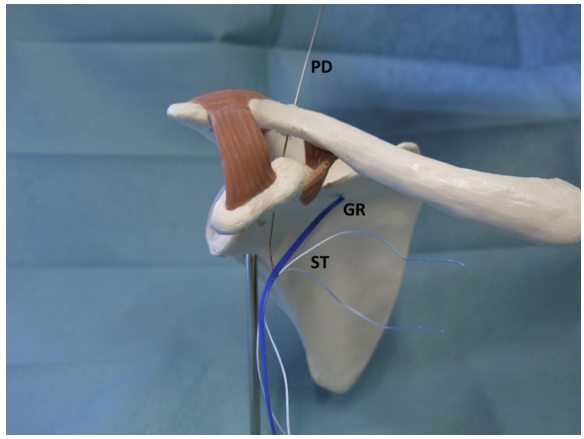

Fig 7. Shoulder model, right shoulder; the strands of the suture tape (ST) (FiberTape, Arthrex) are inserted into a cortical fixation button (DogBone, Arthrex) outside the anteroinferolateral portal. The 2 strands of the suture tape and the Ethibond sutures of one graft end (GR) are threaded inside the passing device (PD).

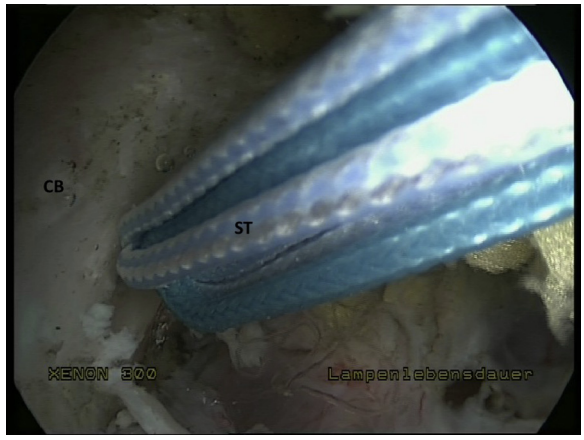

Fig 8. Beach chair position, right shoulder, arthroscopic view from the trans-supraspinatus portal; using a passing suture, strands of a suture tape (ST) (FiberTape, Arthrex) along with the Ethibond sutures of one end of the graft are pulled through the bone tunnel from inferior to superior through the anteroinferolateral portal. (CB, coracoid base.)

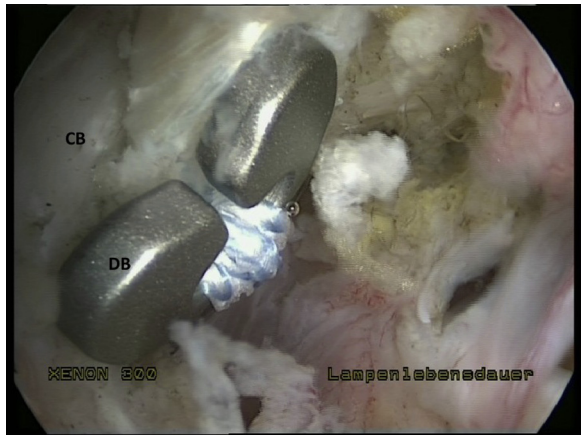

Fig 9. Beach chair position, right shoulder, arthroscopic view from the trans-supraspinatus portal; the cortical fixation button (DogBone [DB], Arthrex) is positioned at the undersurface of the coracoid process (CB) and above the graft by pulling on the suture tapes.

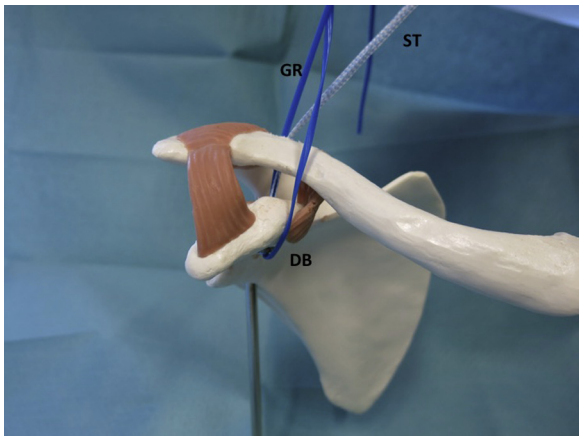

Fig 10. Shoulder model, right shoulder, view from the anterosuperior portal; the free end of the graft (GR) is pulled superiorly in front of the clavicle using a grasper (e.g., FiberTape Retriever, Arthrex). (DB, DogBone; ST, suture tape.)

ligaments. A flexible passport cannula (4 cm, Arthrex, Naples, FL) is inserted to facilitate suture and graft management (Fig 1).

A high trans-supraspinatus portal is established directly behind the long head of the biceps tendon. The arthroscope is switched into this portal for better visualization of the subcoracoid space. Care must be taken not to damage the rotator cable (Fig 2).

Step 4: Coracoid Preparation

Under direct visualization the coracoid is identified, and the undersurface is skeletonized using a radiofrequency device (OPES, Arthrex) (Fig 3).

Step 5: Superior Approach to Lateral Clavicle

A 2- to 3-cm incision is made in line with the lateral clavicle 3.5 to 4.5 cm medial to the AC joint line. The deltotrapezial fascia is incised and mobilized to allow adequate repair. Two Hohmann retractors are inserted to expose the distal clavicle.

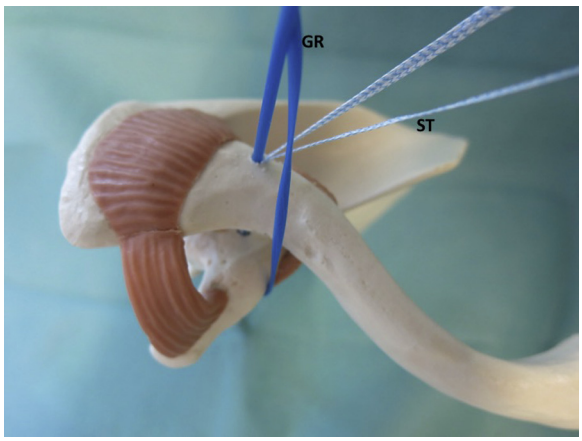

Fig 11. Shoulder model, right shoulder, view from above; the free end of the graft (GR) is pulled superiorly in front of the clavicle using a grasper (e.g., FiberTape Retriever, Arthrex). (ST, suture tape.)

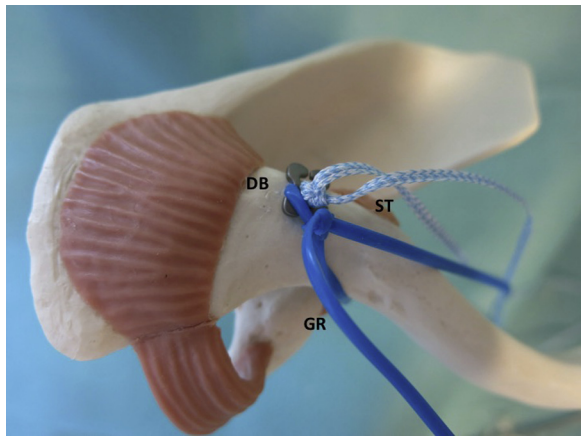

Fig 12. Shoulder model, right shoulder, view from above; after the acromioclavicular joint is reduced, the 2 strands of the suture tape (ST) are knotted over a second cortical fixation button (DB) on the distal clavicle. After correct joint reduction is confirmed by fluoroscopy, the free ends of the graft (GR) are also knotted together over the clavicle leaving one long end.

Step 6: CC Fixation

For CC fixation a drill guide is used to place a K-wire through the distal clavicle at the level between the conoid and trapezoid ligament insertion and through the center of the coracoid base (Fig 4). Correct positioning of the K-wire is confirmed by direct visualization and fluoroscopy. Next, the K-wire is overdrilled using a cannulated 4-mm drill and the K-wire is removed (Fig 5). A suture-passing device is inserted through the cannulated drill and removed through the anteroinferolateral portal (Fig 6). A cortical fixation

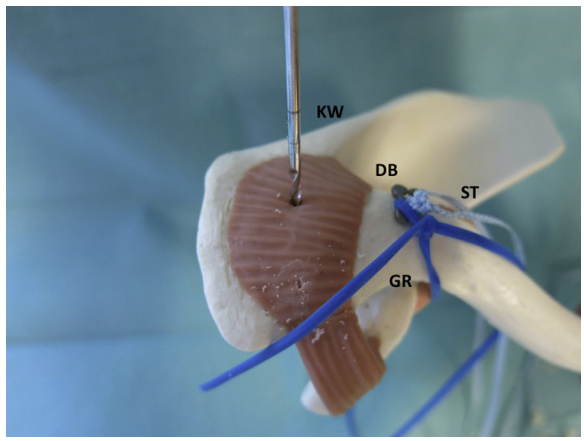

Fig 13. Shoulder model, right shoulder, view from above; two 4-mm drill holes are placed through the acromion in the craniocaudal direction, approximately 1 cm lateral to the AC joint line. (AC, acromioclavicular; DB, DogBone; GR, graft; KW, K-wire; ST, suture tape.)

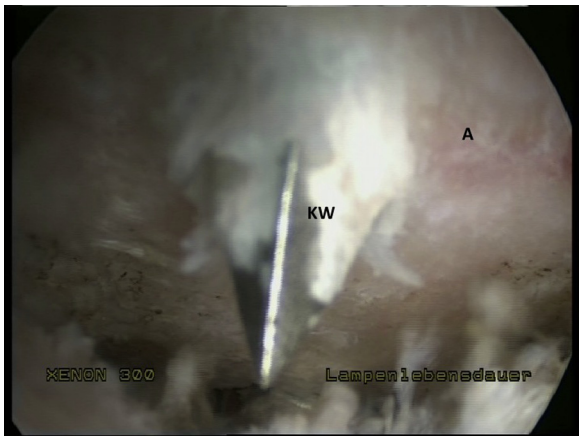

Fig 14. Beach chair position, right shoulder, arthroscopic view from the posterior portal, subacromial, inserted K-wire (KW) through the acromion (A).

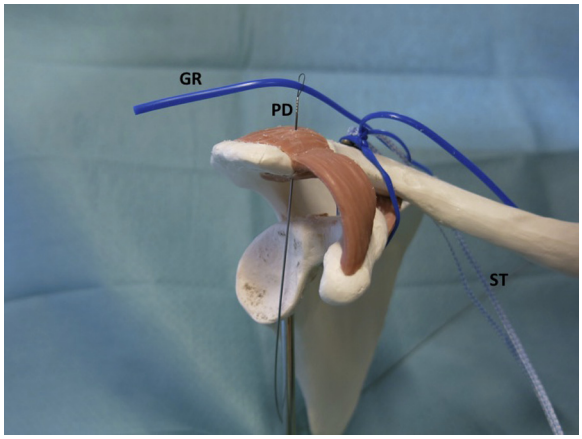

Fig 15. Shoulder model, right shoulder, view from the lateral portal; a shuttle wire (PD) is needed to pull the graft (GR) into the subacromial space through the anterior acromial drill hole. (ST, suture tape.)

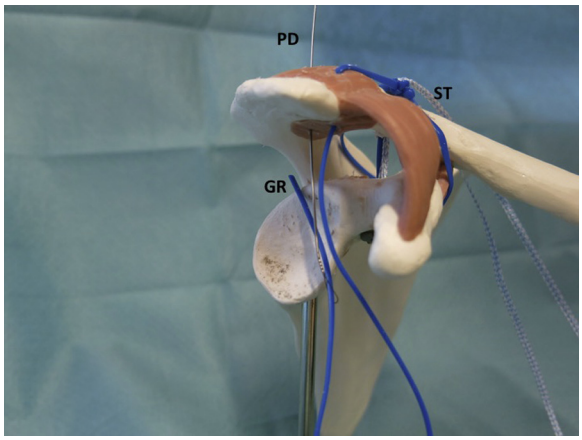

Fig 16. Shoulder model, right shoulder, view from the lateral portal; using a shuttle suture (PD), the graft (GR) is pulled into the subacromial space through the anterior acromial drill hole. Next, again a passing wire (PD) is used to pull the graft (GR) upward through the posterior drill hole. (ST, suture tape.)

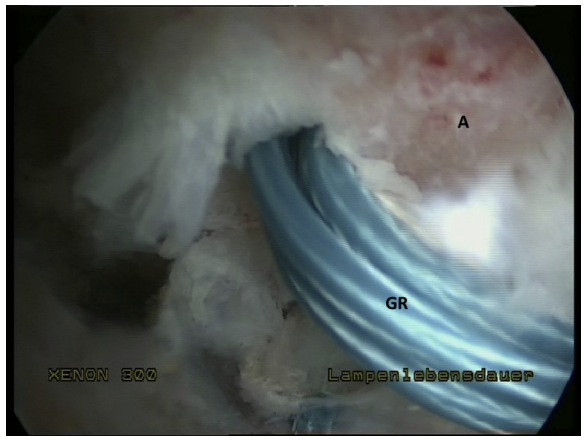

Fig 17. Beach chair position, right shoulder, arthroscopic view from the posterior portal; using a shuttle suture, the graft (GR) is pulled into the subacromial space through the anterior acromial drill hole. Next, again a passing wire is used to pull the graft upward through the posterior drill hole. (A, acromion.)

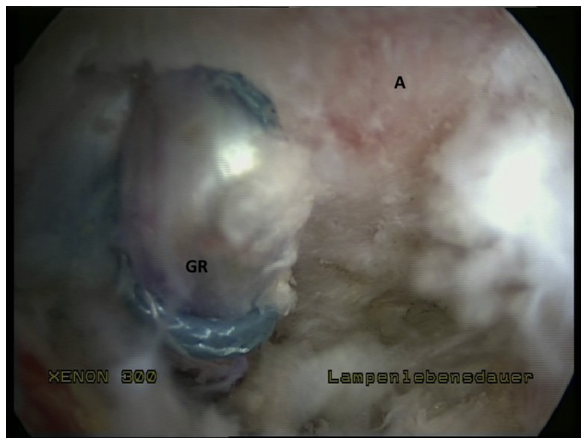

Fig 18. Beach chair position, right shoulder, arthroscopic view from the posterior portal, subacromial graft placement (GR) after shuttling. (A, acromion.)

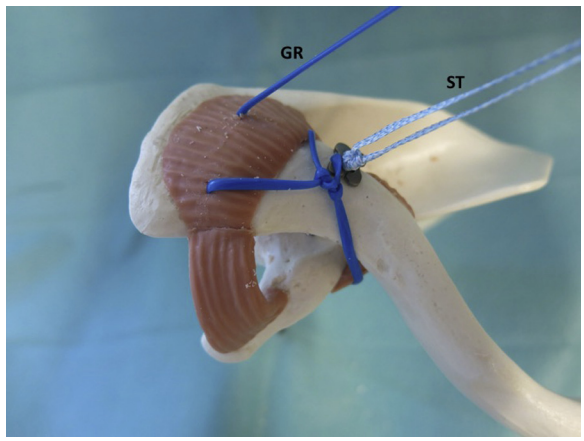

Fig 19. Shoulder model, right shoulder, view from above; the ends of the suture tapes (ST) and the end of the graft (GR) are knotted together, thus creating a trapezoidal acromioclavicular graft augmentation. The free ends are cut.

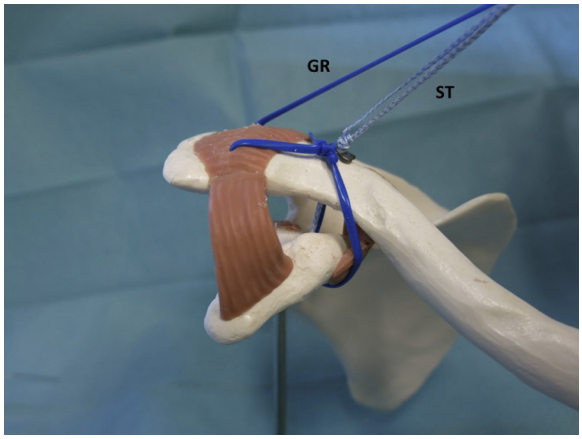

Fig 20. Shoulder model, right shoulder, view from the anterosuperior portal; the ends of the suture tapes (ST) and the end of the graft (GR) are knotted together, thus creating a trapezoidal acromioclavicular graft augmentation. The free ends are cut.

button (DogBone, Arthrex) is put onto the suture tape outside the anteroinferolateral portal. Using a passing suture, the 2 strands of a suture tape (FiberTape, Arthrex) along with the Ethibond sutures of one graft end are threaded (Fig 7) and then pulled through the bone tunnel from inferior to superior (Fig 8). By pulling the cortical fixation button (DogBone, Arthrex) is placed onto the suture tape under the coracoid process and above the graft (Fig 9). The free end of the graft is then pulled superiorly in front of the clavicle using a grasper (e.g., FiberTape Retriever, Arthrex) (Figs 10 and 11).

Step 7: Reduction and Fixation

At this point, the AC joint is reduced and fixed by knotting the 2 strands of suture tape over a second cortical fixation button on the distal clavicle. After the correct joint reduction is confirmed by fluoroscopy, the free ends of the graft are knotted together over the clavicle leaving one long end (Fig 12). The knot is secured with 3 Ethibond sutures.

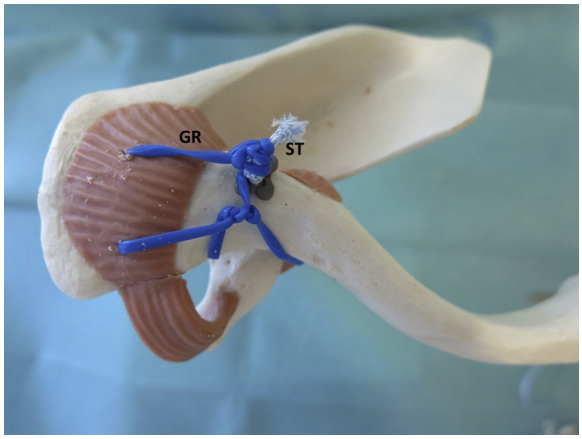

Fig 21. Shoulder model, right shoulder, view from above; graft (GR)/suture tape (ST)/DogBone construct after knotting and cutting the free ends.

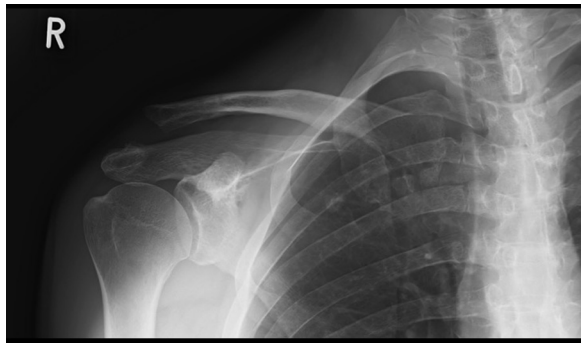

Fig 22. Conventional anteroposterior radiographic view before surgery.

Step 8: AC Augmentation

The arthroscope is then placed in the subacromial space and an anterolateral portal is established. Two 4-mm drill holes are placed through the acromion in craniocaudal direction, approximately 1 cm lateral to the AC joint line (Figs 13 and 14). For proper drill hole placement and stability, one drill hole is placed within the anterior third and the other one in the posterior third referring to the AC joint line in the anteroposterior direction. The long end of the graft is shuttled laterally and over the AC joint by the use of an overhold for tunneling. Again, a shuttle wire is needed to pull the graft into the subacromial space through the anterior acromial drill hole (Fig 15). A grasper can be used as hypomochlion through the anterolateral portal to facilitate graft passage. Next, the procedure is repeated to bring the graft upward through the posterior drill hole (Figs 16-18). The ends of the suture tapes and the end of the graft are then knotted together, thus creating a trapezoidal AC graft augmentation. The free ends are cut (Figs 19-21). Finally, the deltotrapezial fascia is reconstructed and wound closure is performed in a standard fashion. Pre- and

Fig 23. Conventional anteroposterior radiographic view after surgery.

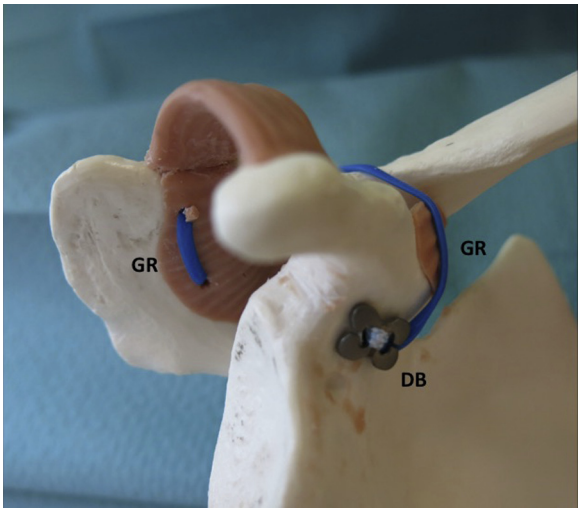

Fig 24. Shoulder model, right shoulder, view from inferior, showing looping one strand of the graft (GR) in front of the clavicle and the other end through the coracoid base and distal clavicle. After knotting both ends above the clavicle, the longer strand is used to create the AC augmentation. (AC, acromioclavicular; DB, DogBone.)

postoperative radiographs are shown in Figures 22 and 23, respectively.

Discussion

For many years, the modified Weaver-Dunn procedure presented the gold standard in AC joint reconstruction, especially for chronic cases. However, studies using graft augmentation have shown to provide superior stability than the modified Weaver-Dunn procedure.[13] In addition, Mazzocca et al.[12] described an anatomic graft reconstruction of the conoid and trapezoid ligaments with almost equal biomechanical conditions compared with the native joint.

Today, using tendon grafts for chronic AC joint instability reconstruction is an established method.[8,10,11] For most techniques, nonbiologic suture button systems are used for allowing a proper healing process of the graft components.[10,14,20]

In a recent study, Scheibel et al.[21] described persistent horizontal instability in 41% cases after isolated CC double ligament stabilization. Saier et al.[22] could show biomechanically that only combined AC and CC reconstruction can adequately restore physiological horizontal AC joint stability. In addition, a recently published study showed that triple-bundle reconstruction including AC graft augmentation yielded superior clinical and radiological outcome than single-bundle CC reconstruction.[14] However, the graft augmentation techniques introduced complications such as rupture of the graft, hardware failure, and fracture of the clavicle or coracoid through bone tunnels due to decreased bone strength.[16-18]

Therefore, we present an arthroscopic technique for biological reconstruction of the AC and CC ligaments protected by a suture tape construct for chronic AC joint instability.

This technique minimizes the bone tunnels by looping the graft in front of the clavicle (Fig 24) and uses less and smaller (4-mm) drill holes within the distal clavicle and the coracoid process (Table 2) than previously described.[12] This graft and button-suture tape construct enhances horizontal and vertical stability of the AC joint.

The technique has shown to provide excellent clinical results without observing a fracture in the distal clavicle, coracoid, or acromion.

Table 2. Pearls and Pitfalls

Correct direction of the K-wire aiming device for coracoclavicular drilling: posterior third of the clavicle and in reference close to the coracoid base
Use of fluoroscopy to ensure correct drilling and reduction of the acromioclavicular joint
Thorough subcoracoid and subacromial debridement is necessary before drilling
Graft should be measured at least 18-20 cm

References

1. Braun S, Martetschläger F, Imhoff AB. Acromioclavicular joint injuries and reconstruction. In: Doral NM, Karlsson J, eds. *Sports injuries: Prevention, diagnosis, treatment and rehabilitation*. Berlin, Heidelberg: Springer, 2015;1-12.
2. Fraser-Moodie JA, Shortt NL, Robinson CM. Injuries to the acromioclavicular joint. *J Bone Joint Surg Br* 2008;90:697-707.
3. Glick JM, Milburn LJ, Haggerty JF, Nishimoto D. Dislocated acromioclavicular joint: Follow-up study of 35 unreduced acromioclavicular dislocations. *Am J Sports Med* 1977;5:264-270.
4. Lemos MJ. The evaluation and treatment of the injured acromioclavicular joint in athletes. *Am J Sports Med* 1998;26:137-144.
5. Spencer EE Jr. Treatment of grade III acromioclavicular joint injuries: A systematic review. *Clin Orthop Relat Res* 2007;455:38-44.
6. Beitzel K, Cote MP, Apostolakos J, et al. Current concepts in the treatment of acromioclavicular joint dislocations. *Arthroscopy* 2013;29:387-397.
7. Weinstein DM, McCann PD, McIlveen SJ, Flatow EL, Bigliani LU. Surgical treatment of complete acromioclavicular dislocations. *Am J Sports Med* 1995;23:324-331.
8. Rolf O, Hann von Weyhern A, Ewers A, Boehm TD, Gohlke F. Acromioclavicular dislocation Rockwood III-V: Results of early versus delayed surgical treatment. *Arch Orthop Trauma Surg* 2008;128:1153-1157.
9. Tauber M, Eppel M, Resch H. Acromioclavicular reconstruction using autogenous semitendinosus tendon graft: Results of revision surgery in chronic cases. *J Shoulder Elbow Surg* 2007;16:429-433.

10. Braun S, Martetschlager F, Imhoff AB. [Arthroscopically assisted reconstruction of acute and chronic AC joint separations]. *Oper Orthop Traumatol* 2014;26:228-236 [in German].
11. Warth RJ, Martetschlager F, Gaskill TR, Millett PJ. Acromioclavicular joint separations. *Curr Rev Musculoskelet Med* 2013;6:71-78.
12. Mazzocca AD, Santangelo SA, Johnson ST, Rios CG, Dumonski ML, Arciero RA. A biomechanical evaluation of an anatomical coracoclavicular ligament reconstruction. *Am J Sports Med* 2006;34:236-246.
13. Tauber M, Gordon K, Koller H, Fox M, Resch H. Semitendinosus tendon graft versus a modified Weaver-Dunn procedure for acromioclavicular joint reconstruction in chronic cases: A prospective comparative study. *Am J Sports Med* 2009;37:181-190.
14. Tauber M, Valler D, Lichtenberg S, Magosch P, Moroder P, Habermeyer P. Arthroscopic stabilization of chronic acromioclavicular joint dislocations: Triple- versus single-bundle reconstruction. *Am J Sports Med* 2016;44:482-489.
15. Weaver JK, Dunn HK. Treatment of acromioclavicular injuries, especially complete acromioclavicular separation. *J Bone Joint Surg Am* 1972;54:1187-1194.
16. Martetschlager F, Horan MP, Warth RJ, Millett PJ. Complications after anatomic fixation and reconstruction of the coracoclavicular ligaments. *Am J Sports Med* 2013;41:2896-2903.
17. Spiegl UJ, Smith SD, Euler SA, Dornan GJ, Millett PJ, Wijdicks CA. Biomechanical consequences of coracoclavicular reconstruction techniques on clavicle strength. *Am J Sports Med* 2014;42:1724-1730.
18. Martetschlager F, Saier T, Weigert A, et al. Effect of coracoid drilling for acromioclavicular joint reconstruction techniques on coracoid fracture risk: A biomechanical study. *Arthroscopy* 2016;32:982-987.
19. Brady P. Editorial commentary: The larger holes or larger number of holes we drill in the coracoid, the weaker the coracoid becomes. *Arthroscopy* 2016;32:988-989.
20. Scheibel M, Ifesanya A, Pauly S, Haas NP. Arthroscopically assisted coracoclavicular ligament reconstruction for chronic acromioclavicular joint instability. *Arch Orthop Trauma Surg* 2008;128:1327-1333.
21. Scheibel M, Droschel S, Gerhardt C, Kraus N. Arthroscopically assisted stabilization of acute high-grade acromioclavicular joint separations. *Am J Sports Med* 2011;39:1507-1516.
22. Saier T, Venjakob AJ, Minzlaff P, et al. Value of additional acromioclavicular cerclage for horizontal stability in complete acromioclavicular separation: A biomechanical study. *Knee Surg Sports Traumatol Arthrosc* 2015;23:1498-1505.